

Managing airway obstruction

Introduction

Recognizing airway compromise is a fundamental skill for junior doctors as they will frequently be first managing these patients. By appreciating the causes of an obstructed airway, treatment with oxygen and a number of simple manoeuvres can be delivered swiftly, preserving airway patency and passage of oxygen to the lungs for ventilation. Ventilation is the mechanical movement of air into and out of the respiratory system, resulting in the exchange of carbon dioxide.

Airway obstruction results in hypoventilation, increased work of breathing and impaired gas exchange, with development of hypercarbia and ultimately hypoxaemia if left untreated. Provision of supplemental oxygen in the setting of airway obstruction (i.e. oxygenation) will not resolve the problem of hypercapnia associated with hypoventilation and impaired alveolar ventilation. Obstruction may be partial or complete, depending on the mechanism or cause. Complete airway obstruction will rapidly cause hypoxia and cardiac arrest, whereas partial obstruction may be more insidious in onset. Reduced alveolar ventilation in the obtunded patient and the obstructed airway leads to hypercapnia, respiratory acidosis and hypoxaemia. Noisy breathing characterizes a partially obstructed airway, and ominous absence of airway noises heralds total airway obstruction

Causes of an obstructed airway

The airway may be subdivided into upper and lower airway – the upper airway comprises the conduit from the nares and lips to the larynx, while the lower airway contains the tracheobronchial tree, consisting of 23 generations of passages from trachea to alveoli. The level of obstruction will

commonly be related to the cause or pathogenesis of disease process.

There are a large number of causes of airway obstruction (*Table 1*), and it is important to look out for at-risk groups in whom airway compromise is more common. Patients with a reduced conscious level are unable to clear their own secretions and cannot protect their own airway. A Glasgow Coma Scale of 8/15 or below is often considered the threshold at which intubation is necessary. Patients with reduced conscious level are at risk of aspiration and alveolar hypoventilation, with development of hypercarbia and respiratory acidosis.

In practice, a more focused approach is taken when deciding to intubate patients, bearing in mind factors such as the potential for further deterioration, and moving from a place of safety to one of greater isolation (e.g. transfer from resuscitation department to radiology department). In these instances, a more conservative approach is taken, and patients with a higher Glasgow Coma Scale may warrant early intubation.

Also, think about patients in whom surgery, trauma or burns may contribute to airway compromise, e.g. from haematoma and oedema. In the case of burns or history of smoke inhalation, adopt a high index of suspicion for airway injury. Signs such as carbonaceous sputum, soot around the face and mouth, and singed hair warrant urgent anaesthetic input. These patients must always be assessed early by an anaesthetist, as these are

dynamic situations that may rapidly progress from one of stability to one of a threatened and compromised airway. As such early intubation is undertaken in these at-risk groups.

External compression from an adjacent pathology, e.g. goitre, lymphadenopathy, tumour and haematoma (e.g. post-thyroidectomy), may be insidious or rapid in onset. In patients with underlying malignancy, it is important for clinicians to be vigilant in identifying features suggestive of airway compromise.

Airway obstruction may occur at any point from the mouth down to the trachea and bronchial tree. The commonest site for obstruction in the obtunded unconscious patient is at the pharynx, because the tongue falls back against the posterior pharyngeal wall, and a lack of muscle tone causes narrowing of the airway diameter.

The soft tissues in the pharynx and larynx are vulnerable to swelling and oedema if traumatized, or at the site of infection. Post-extubation laryngeal oedema may be seen after traumatic and multiple attempts at intubation, and in patients receiving prolonged periods of intubation where high cuff pressures may cause oedema of laryngeal mucosa. Local trauma following foreign body ingestion, e.g. a fish bone embedded in soft pharyngeal tissues, can cause significant airway compromise, and in some cases development of pharyngeal abscess. In children, whose airways are relatively smaller, mucosal swelling, upper respiratory obstruction and stridor may be associated with infections such as laryngo-

Table 1. Classifying causes of airway obstruction

Mode of obstruction	Example
Intraluminal contents	Blood, vomitus, foreign body, secretions, intraluminal tumours
Central drive (obtunded)	Head injury (with reduced conscious level), drugs: benzodiazepine, opiates, alcohol, raised intracranial pressure
External compression	Haematoma, tumour, goitre
Direct trauma	Blunt trauma to maxilla, larynx, mandible, burns, smoke inhalation
Artificial airways	Blockage or displacement of tracheostomy, displacement of tracheal stent
Excessive granulation tissue	Prolonged mechanical ventilation, tracheal stenosis, supraglottic stenosis
Neurocognitive and neuromuscular disorders	Increased risk of aspiration, e.g. Parkinson's disease, post-stroke, myasthenia gravis

Dr Kirstie McPherson is Specialist Registrar in Anaesthesia and **Dr Robert CM Stephens** is Consultant Anaesthetist in the Department of Anaesthetics, University College Hospital, London NW1 2BU

Correspondence to: Dr K McPherson (kirstmcp@gmail.com)

tracheobronchitis (croup) and epiglottitis. The latter (seen less following the advent of widespread vaccination) causes enlargement of the epiglottis, and may progress to complete airway obstruction. Classically children will adopt a sitting 'tripod' position, with jaw thrust forward and drooling saliva. The importance of getting expert help swiftly cannot be over-emphasized if these pathologies are suspected. Distress and examination of the pharynx may precipitate complete airway obstruction. Get help early.

Upper airway stimulation in the presence of secretions or inhalation of foreign material may cause laryngeal spasm with adduction of the vocal cords, preventing passage of air to the lungs and leading to development of hypoxaemia.

Recognizing airway obstruction

It is important to assess airway patency in any patient at risk of airway obstruction. This forms part of the ABC approach, sequentially assessing airway, breathing and circulation as described by Nolan et al (2010) in life support algorithms.

A conscious and alert patient, speaking in full sentences, is reassuring. Features suggestive of obstructed airway include complete absence of airway sounds (complete obstruction), or added sounds of laboured breathing where air entry is diminished (partial obstruction). Tachycardia and tachypnoea may reflect respiratory distress (Table 2).

Use of accessory muscles of respiration is typical in the partially obstructed airway, and signs include tracheal tug, paradoxical chest and abdominal movement ('see-sawing'), with supraclavicular and intercostal in-drawing. Stridor is the harsh, high-pitched sound occurring in upper airway obstruction. Its origin is from the Latin *stridere*, 'to creak'. Inspiratory stridor indicates laryngeal obstruction, since the nega-

tive intrathoracic pressures exacerbate extrathoracic obstruction during inspiration. Intrathoracic obstruction may cause expiratory stridor, as the airways are compressed during expiration. Children are more susceptible to stridor, given the relatively smaller diameter of their airways.

Irritability, agitation and reduced conscious level commonly reflect hypoxaemia and hypercarbia. Do not rely on cyanosis as a feature in identifying the obstructed airway – this is a very late preterminal sign.

Observe or ask about 'best breathing position'. Be aware that the patient may have positioned him-/herself for optimal airflow in the setting of airway obstruction. Moving the patient into a supine position may precipitate loss of the airway altogether.

Low pulse oximetry readings (SpO_2) reflect inadequacy of oxygenation, although it is important to remember that pulse oximetry provides a measure of oxygenation and is not the same as ventilation. Arterial blood gas sampling may be helpful but should not delay management. A respiratory acidosis, with a high carbon dioxide tension ($PaCO_2$) and reduced pH, reflects alveolar hypoventilation.

When assessing patients look carefully for these signs and symptoms and always call for help early from an anaesthetist if you suspect airway compromise. The young can compensate well initially, masking impending desaturation and hypoxaemia. Be mindful of injuries that will compromise the airway, such as facial burns, bleeding and foreign bodies obstructing the airway. Always provide high flow oxygen with a reservoir bag at 15 litres/minute, and reassess frequently, looking for signs of deterioration.

Managing a compromised airway

Oxygen therapy is required urgently in the obstructed airway. An oxygen mask with

reservoir bag and an oxygen flow rate of 15 litres/minute will provide a high inspired fraction of oxygen, and can be found on all wards and resuscitation areas. Remember blood oxygen saturation will be restored more quickly if the inspired fraction of oxygen is high.

The recovery (lateral) position pushes the tongue and jaw forward under gravity, improving the airway. This position is one of relative safety for patients with a depressed conscious level, e.g. as a result of alcohol excess, or in a post-ictal state. In addition, a head-down tilt (tilting facility available on most hospital trolleys) provides passage for secretions or vomit out of the mouth, with the help of gravity.

Patients with an artificial airway, e.g. tracheostomy, with features of respiratory distress require urgent and skilled airway help. Do not delay in summoning immediate assistance from an anaesthetist. These devices may have become blocked or displaced. Apply high flow oxygen to both the face and the tracheostomy.

Simple manoeuvres

Simple manoeuvres in an obtunded patient may help to improve the patency of the airway, allowing passage of air into and out of the lungs. These are described below. Practice them on a manikin or in theatre with an anaesthetist.

Chin lift

Head tilt and chin lift can be used to relieve upper airway obstruction. Place the fingertips underneath the patient's chin and gently lift upwards.

Jaw thrust

The jaw thrust is achieved by combined flexion of the neck and extension at the atlanto-occipital joint, lifting the angles of the mandible forward (Figure 1). This

Figure 1. Jaw thrust.

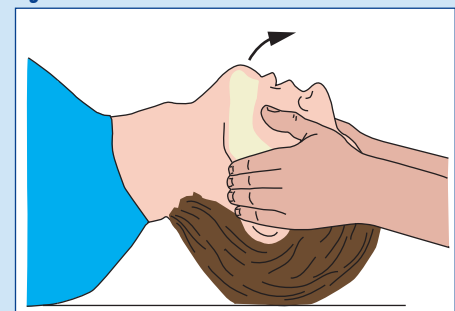


Table 2. Features of airway obstruction

Snoring
Stridor (caused by obstruction at or above the laryngeal level)
Expiratory wheeze (caused by obstruction of lower airways)
Gurgling (vomit, blood or secretions in airway)
Reduced conscious level
'Tripod positioning' seen in children (for maximal air passage to lungs)

manoeuvre lifts the tongue and moves the larynx forward, allowing passage of air into the lungs.

Cautionary points

Avoid neck extension and risks to the spinal cord in patients in whom a cervical spine injury is suspected. In these patients jaw thrust in combination with manual in-line stabilization is recommended.

Upward pressure on the soft tissues of the floor of the mouth in young children can cause obstruction. Be mindful of this when performing jaw thrust in this population.

Adjuncts

The oropharyngeal airway (Guedel) and nasopharyngeal airway are simple adjuncts, useful in maintaining a patent airway (*Figure 2*). They relieve backward tongue displacement and soft palate obstruction. Careful insertion under direct vision is important. Avoid using a nasopharyngeal airway in patients for whom a base of skull fracture or coagulopathy is suspected.

An oropharyngeal airway is sized by measuring the distance from the incisors to the angle of the jaw. The most common technique for placing an oropharyngeal airway is by inserting the airway into the mouth upside-down, and then rotating through 180° at the junction between the soft and hard palate. The airway is then advanced until it rests in the pharynx. Suction should always be available to clear the airway of any visible secretions or foreign body.

Conscious patients, in whom laryngeal reflexes are present, will not tolerate an oropharyngeal airway and inserting one may precipitate gagging, vomiting and laryngospasm.

Bag-valve-mask ventilation

Patients with reduced conscious level and inadequate spontaneous ventilation will require artificial ventilation in addition to the manoeuvres described above. Connect a bag-valve-mask apparatus (ambu-bag) to a high flow oxygen source (this should be

available on all wards and resuscitation areas). This will require a two-person technique to achieve a gas-tight seal between the patient's face and the mask, enabling ventilation without leak. One person should hold the mask onto the face, maintaining a jaw thrust, while the assistant squeezes the bag.

Laryngeal mask airway

Should bag-valve-mask ventilation prove difficult with the two-person technique and the use of the oropharyngeal airway adjunct, alternative means of ventilation are needed. In these instances, senior support should be sought early, with involvement of an anaesthetist with expert airway management skills.

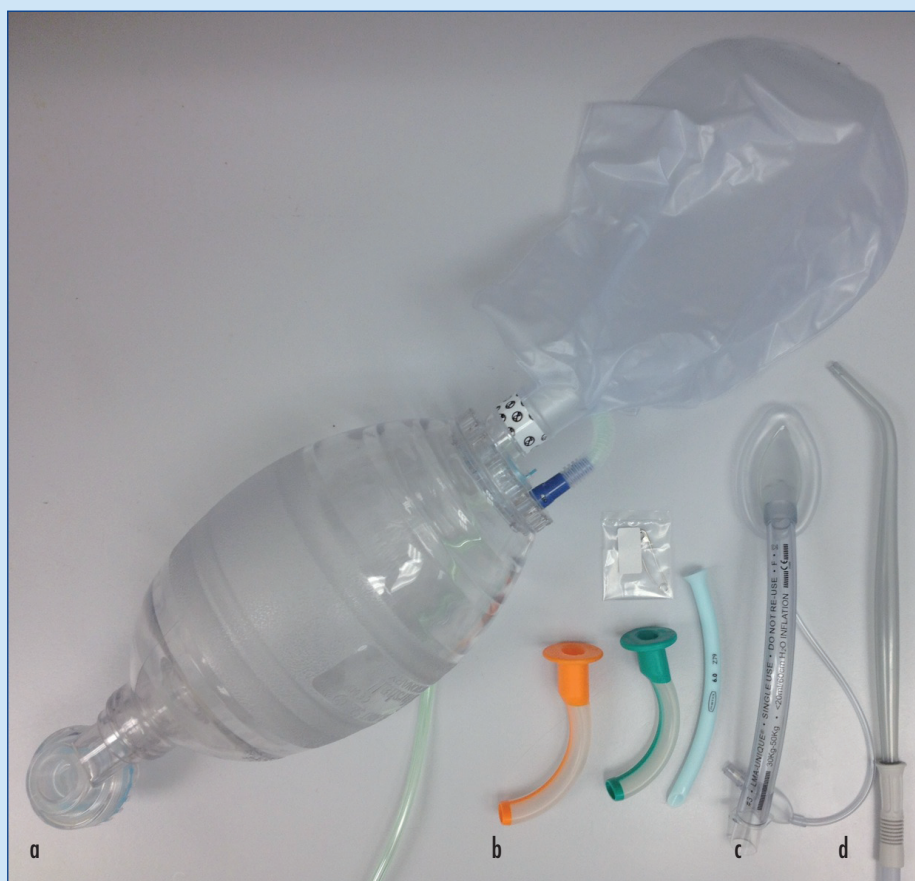The laryngeal mask airway is a device for supporting and maintaining the airway without tracheal intubation. It does not protect the airway from soiling unlike tracheal intubation and is not a secure airway. However, it may serve as an interim measure in the unconscious patient, when intubation has failed, or lack of skill and experience precludes intubation. The head of the laryngeal mask is inserted into the mouth to lie against the back of the pharynx. A circumferential cuff is then inflated to provide an adequate seal to enable ventilation. The end can then be connected to an ambu-bag device to provide artificial ventilation. Incorrect placement increases the risk of aspiration of stomach contents, as the stomach may become gas-filled during ventilation.

The laryngeal mask does not guarantee protection from aspiration of gastric contents into the bronchial tree and will not be tolerated in patients in whom laryngeal reflexes are preserved. Again, try to familiarize yourself with the insertion technique with practice on a manikin, or under supervision from an anaesthetist in theatre.

Securing an airway

A secure airway is one in which the trachea and bronchial tree are protected from aspiration of gastric contents or secretions by the presence of a cuffed endotracheal tube (or a tracheostomy). This is the gold standard for an unconscious patient at risk of aspiration, but should only be attempted by those trained and familiar with the technique of tracheal intubation. This will

Figure 2. Adjuncts for supporting airway and laryngeal mask. a. Bag-valve-mask system with high flow oxygen source. b. Oropharyngeal and nasopharyngeal airways. c. Laryngeal mask. d. Wide-bore rigid sucker.



most frequently be the anaesthetist, and it is important to stress again the importance of calling early for help and advice from an anaesthetist in patients with a reduced conscious level.

Meticulous attention to detail is needed when preparing for intubation, to avoid mishaps and potentially life-threatening consequences of aspiration and hypoxia. Equipment required for intubation includes an appropriately sized endotracheal tube, a tie to secure it, a laryngoscope (with alternative blade size available), and equipment on standby should intubation prove difficult (*Figure 3*). This includes a gum-elastic bougie, and alternative means of ventilating, e.g. with a laryngeal mask airway. An ambu-bag or alternative means of ventilation connected to a high flow oxygen source will be connected to the endotracheal tube once in place. Guidelines published by the Difficult Airway Society (Henderson et al, 2004) provide algorithms on procedure for failed intubation, and it is advisable to be familiar with these if you have responsibility for managing airways in patients.

Most importantly, a trained anaesthetic nurse or practitioner must assist, and all equipment needs checking and carefully assembly before commencing intubation.

In an emergency setting, where patients are not starved and are at risk of aspiration, a rapid sequence induction for tracheal intubation is performed. Anaesthesia

and relaxation of the vocal cords must be provided for passage of the endotracheal tube into the trachea. Given the risk of aspiration in a population presenting with reduced conscious level, a rapid sequence induction provides these optimal conditions in the larynx with rapid onset.

Preparation is vital for rapid sequence induction, as the anaesthetist needs to react quickly in the event of aspiration. Drugs are prepared beforehand and the tilting capacity of the trolley is confirmed, with suction (wide bore rigid sucker) under the pillow (important in the event of aspiration).

The patient is preoxygenated with a tight-fitting mask, for at least 3 minutes or until end-tidal oxygen fraction >0.8 . Reassure the patient about what is happening and when possible explain your actions, as this will be an alarming time for the patient. Before loss of consciousness, cricoid pressure is applied – pressure with the thumb and index finger over the cricoid cartilage (used since it forms the only complete ring of the larynx and trachea). Pressure over this cartilage displaces the larynx backwards, compressing the oesophagus between the cricoid cartilage and the vertebrae behind. This prevents passive regurgitation of gastric contents during induction of anaesthesia. In the event of active vomiting, cricoid pressure should be released, as this could cause

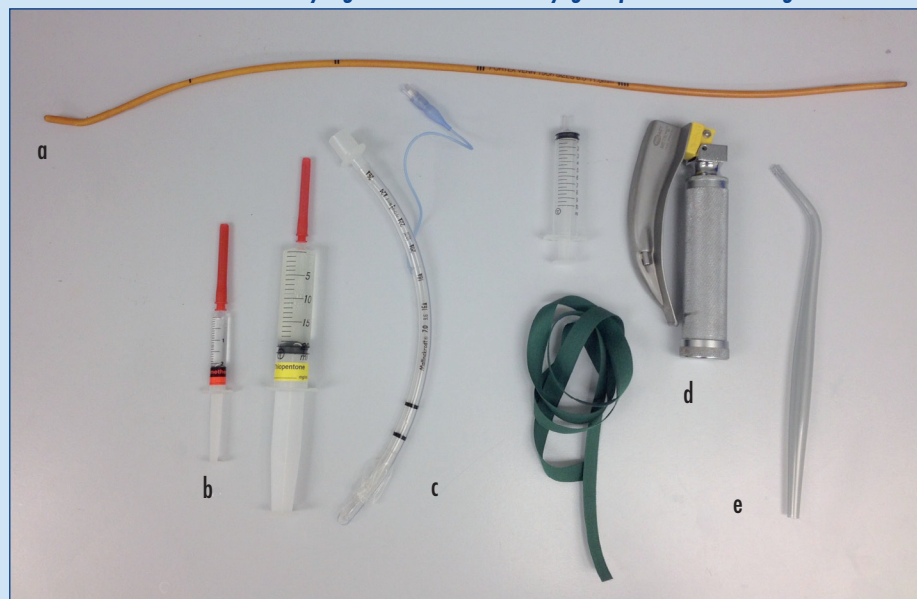
rupture of the oesophagus. Pressure is applied until the anaesthetist has confirmed placement of the endotracheal tube with the cuff inflated. Incorrectly performed cricoid pressure may distort the laryngeal anatomy, making successful laryngoscopy extremely difficult for the operator.

A rapid sequence induction comprises quick intravenous induction of anaesthesia and neuromuscular blockade facilitating intubation. Following administration of these drugs, laryngoscopy may be performed securing the airway with a cuffed endotracheal tube in the trachea to prevent further soiling of the airway.

The combination of thiopentone and suxamethonium have been described in the classical rapid sequence induction, and while still in use, a greater variety of drugs are now used in a modified rapid sequence induction, largely for their superior side-effect profile, as demonstrated by Morris and Cook (2001) in a national survey of practice of the technique. A predetermined dose of induction agent is administered, followed by a muscle relaxant, with rapid onset of action. This negates the need to provide facemask ventilation while waiting for onset of neuromuscular blockade, which risks insufflation of the stomach and aspiration of its contents. The choice of drugs used will depend on both the pharmacodynamic characteristics and the experience of the doctor. The dose should reflect the haemodynamic status of the patient, and hypotension should be anticipated, with readily available provision for vasopressors and sufficient intravenous access to optimize preload.

After successful intubation with connection of the tracheal tube to a ventilating device, checks must be carried out to confirm correct placement of the tube in the trachea. These include auscultation of both lungs, observing chest movement, fogging of the tube as warm humidified air is expired from the lungs and capnography confirming the presence of end-tidal carbon dioxide. Consecutive breaths seen on capnography remain the gold standard for ruling out oesophageal intubation, and guidelines published by the Association of Anaesthetists of Great Britain and Ireland (2011) require its provision for all anaesthetized patients and those undergoing

Figure 3. Equipment required for intubation. a. Gum elastic bougie. b. Suxamethonium and thiopentone. c. Endotracheal tube with tie and syringe to inflate cuff. d. Laryngoscope. e. Wide bore rigid sucker.



advanced life support, regardless of the location of the patient. A flat capnograph trace indicates lack of ventilation of the lungs: the tube is either not in the trachea or the airway is completely obstructed. Only when you are satisfied with the correct placement of the endotracheal tube, should you ask the assistant to release the cricoid pressure.

Failure to identify an endotracheal tube misplaced in the oesophagus will lead to life-threatening hypoxia. The National Audit Project on airway management (Cook et al, 2011) found evidence of avoidable deaths as a result of airway com-

plications in the intensive care unit and the emergency department. Several major events occurred when there were clear indications for a rapid sequence induction but this was not performed. Failure to correctly interpret a capnograph trace led to several oesophageal intubations going unrecognized. The absence of capnography, or the failure to use it properly, contributed to 80% of deaths from airway complications in the intensive care unit and 50% of deaths from airway complications in the emergency department. Active efforts should be taken to positively exclude these diagnoses.

Many of the key findings of the report relate specifically to the vigilant approach that must be taken when performing rapid sequence induction in the emergency department and in settings outside of the safer confines of the anaesthetic room. Most events in the emergency department were complications of rapid sequence induction. Rapid sequence induction outside the operating theatre requires the same level of equipment and support as is needed during anaesthesia. This includes capnography and access for equipment needed to manage routine and difficult airway problems.

KEY POINTS

- Be aware of features of airway compromise, and identify and treat patients with airway obstruction early.
- Call for help early from an anaesthetist, and anticipate deterioration in patients with airway compromise.
- Use of simple airway manoeuvres, with basic adjuncts (as required), will often achieve a patent airway.
- Remember, oxygenation is paramount. Make every attempt to provide high oxygen concentration to patients in whom airway compromise is suspected.
- Delivering oxygen at the mouth that does not reach the alveolus is not a treatment for airway obstruction. These patients require artificial ventilation for adequate gas exchange.
- Call for help early, and prepare for intubation in a timely fashion.
- Recognize the dangerous sequelae of hypoxia and aspiration. Expert help from an anaesthetist will help reduce these risks.
- Practice in a simulation centre and in theatre, with an anaesthetist, will improve your skills in recognizing, managing and treating these patients.

TOP TIPS

- Check all your equipment before using it; inflate and deflate cuffs of laryngeal mask and endotracheal tubes and lubricate well with jelly.
- Always have a variety of sizes available for laryngeal mask or endotracheal tube and oropharyngeal airway insertion.
- Familiarize yourself with the 'kit' available in your own hospital, including that available on airway trolleys in the emergency department and on the resuscitation trolleys found on the wards.
- Think carefully about the safety of your patient when planning a transfer, within or outside of the hospital. Is the airway protected or at risk? An anaesthetist should assess and may decide to pre-emptively secure the airway with an endotracheal tube and artificial ventilation.
- When performing preoxygenation for rapid sequence induction, position the patient semi-inclined, with 'head up' and a tight seal around the face mask to maximize body oxygen stores once the patient is apnoeic.

Conclusions

Recognizing and acting on airway compromise reduces morbidity and mortality in patients. Pulse oximetry is a poor indicator of airway compromise, and falling arterial haemoglobin oxygen saturation reflects depleted stores of oxygen in the lungs and is a late sign of impending hypoxaemia. Basic airway manoeuvres (with supplementary oxygen) will often improve the patency of an obstructed airway. Getting help from an anaesthetist early is a priority. Before definitive control of the airway is possible, provide 100% oxygen with a tight-fitting mask to optimize body oxygen stores. **BJHM**

Conflict of interest: none.

Association of Anaesthetists of Great Britain & Ireland (2011) AAGBI safety statement capnography outside the operating theatre. Updated statement from the Association of Anaesthetists of Great Britain & Ireland (AAGBI) May 2011. www.aagbi.org/sites/default/files/Safety%20Statement%20-%20The%20use%20of%20capnography%20outside%20the%20operating%20theatre%20May%202011_0.pdf (accessed 24 July 2012)

Cook TM, Woodall N, Harper J et al (2011) Fourth National Audit Project. Major complications of airway management in the UK: results of the Fourth National Audit Project of the Royal College of Anaesthetists and the Difficult Airway Society. Part 2: intensive care and emergency departments. *Br J Anaesth* **106**: 632–42

Henderson JJ, Latto IP, Pearce AC, Popat MT (2004) Difficult Airway Society guidelines for management of the unanticipated difficult intubation. *Anaesthesia* **59**: 675–94

Morris J, Cook TM (2001) Rapid sequence induction: a national survey of practice. *Anaesthesia* **56**: 1090–7

Nolan JP, Soar J, Zideman DA et al (2010) European resuscitation council guidelines for resuscitation 2010 section 1 Executive summary. *Resuscitation* **81**: 1219–76